



٣٠٠٠٠٠٦

مجلة جامعة أمّ القري

مجلة فصلية للبحوث العلمية المحكمة

العام ١٤١٢هـ / ١٩٩٢م

العدد السادس

السنة الرابعة



٣٠٠٠٠٠٠٦-٨

## تأثير بعض العقاقير على عدوى التوكسوبلازما الحادة والمزمنة في حيوانات التجارب

د . عبد الرحمن النجار\*  
د . مایسه محمد كامل صبحي\*\*

- 
- \* أستاذ مشارك علم الفارماكولوجي - كلية الطب جامعة القاهرة ، ويعمل طبيباً للأطفال في جامعة أم القرى منذ عام ١٤٠٧ / ١٩٨٧ .
- \*\* أستاذ مشارك علم الطفيليات كلية الطب جامعة القاهرة .
- وقد حصل على دورة تدريبية في التعليم الطبي من جامعة دندي باسكتلندا بالملكة المتحدة) .

# EFFECT OF SOME DRUGS ON ACUTE AND CHRONIC EXPERIMENTAL TOXOPLASMOSIS

El-Naggar,<sup>\*\*\*</sup> A.R.; Sobhy, M.K.;<sup>\*\*</sup> El-Ridi, A.S<sup>\*</sup>.; Hamadto<sup>\*</sup>, H.A.; Marii, N.E.;<sup>\*\*\*</sup> and Nagaty<sup>\*</sup>, IM.

Faculty of Medicine, Cairo<sup>\*</sup> and Zagazig Universities (Parasitology<sup>\*</sup>, Pharmacology<sup>\*\*</sup> and Pathology<sup>\*\*\*</sup> Dept.)

## ABSTRACT

This study was conducted on six groups of mice and rats each of ten, to detect the effect of some drugs on the course of acute and chronic toxoplasmosis. In acute toxoplasmosis, mice were given drugs (praziquantel, levimasole, chloroquine, trimethoprim-sulphamethoxazole, and clindamycin hydrochloride) two days before infection as a single dose, while in chronic toxoplasmosis rats were infected with RH strain of *Toxoplasma gondii* one week before receiving the same drugs mentioned before.

It was found that praziquantel, levimasole and chloroquine phosphate had no effect on acute and chronic toxoplasmosis. While trimethoprim-sulphamethoxazole and clindamycin Hcl produced some effects in both acute and chronic toxoplasmosis.

In acute toxoplasmosis they reduced the mortality rate of infected mice and eradicated the parasite from their peritoneal exudate. While in chronic toxoplasmosis, these drugs ameliorated the histopathological changes in brain, liver and spleen of infected rats.

The therapeutic effects of these drugs need further studies to evaluate their efficacy and dosage in the course of toxoplasmosis.

## INTRODUCTION

*Toxoplasma gondii* is a coccidian protozoan of worldwide distribution , that infects a wide range of animals and birds , but does not appear to cause disease in them . The normal final hosts are strictly the cat and related animals ; the only hosts in which the oocyst producing sexual stage of *Toxoplasma* can occur ( Heyneman , 1981 ) .

Toxoplasmosis is the term applied to aquired or congenital infections of man and other mammals caused by *Toxoplasma-gondii* . It occurs on a wide scale in Egypt particularly among women ( El - Rifaie , 1974 ) . Transmission of the parasite occurs through many routes . It is transmitted transplacentally to foetus in approximately 40% of cases ( El - Desouqi , 1978 & White , 1990 ) , by direct contact in laboratory workers handling the living parasite , or in workers in slaughter houses handling infected meat , and from oocysts in cat faeces , or from tissue cysts in raw or undercooked meat ( Heyneman , 1989 ) . Infection can also be transmitted by blood transfusion and leucocyte transfusion from infected donors ( Siegel et al , 1971 ) .

The course of toxoplasmosis was found to be acute in mice and mostly chronic and latent in rats ( Frenkel , 1953 ) . Organisms ( either sporozoites from oocysts or trophozoites from tissue cysts ) invade the mucosal cells of the cat's gut where they form schizonts and gametocytes , oocysts develop , exit from the host cell into the gut lumen , and pass out via faeces . If these oocysts are ingested by a rodent or other mammal including humans , they establish an infection in which it reproduces asexually . Infection is believed to result in parasitaemia then in localization and multiplication of the organism in various tissues forming viable trophozoites . These trophozo-

ites multiply , break out , and spread the infection to lymph nodes and other organs “ Acute stage of the disease ” , they later penetrate nerve cells especially those of the brain and eye , forming tissue cysts “ Chronic stage of the disease ” ( Schmidt and Roberts , 1985 ) .

In the brain , Beverley ( 1974 ) recorded the occurrence of inflammatory changes in the form round cell infiltrations mainly lymphocytes with some plasma cells and macrophages . The infiltrations tend to be focal in the brain , the larger focal lesions tend to undergo central necrosis . In acute infections , the histopathological studies demonstrated that the liver cells showed degeneration which progressed from hydropic to fatty one , with marked cellular infiltration around blood vessels in the form of granulomata . While in chronic infection most of the liver cells were normal but some foci of necrosis were seen ( Rifaat et al . , 1981 ) . In the spleen of chronically infected animals , the splenic follicles are enlarged with the presence of immunoblasts in the germinal centers , the cords of the red pulp are thickened and contain numerous plasma cells ( Rifaat et al . , 1981 ) .

Extensive experimental works have been performed along the last five decades for detection of effective anti - toxoplasma drugs . Clinically acute infections can be treated with a combination of pyrimethamine « 25mg/day » for 3-4 weeks , and tri-sulfaprimidines « 2-6g/day » for 3-4 weeks . an alternative drug is spiramycin « 2-4g/day » for 3-4 weeks ( Goldsmith , 1989 ) .

This work has been designed to study the effect of some drugs on acute and chronic toxoplasmosis in experimental animals .

## MATERIALS AND METHODS

- **Animals :** Albino Swiss mice , 6-8 weeks old (about 20 g.wt.), and albino rats , 20 weeks old (about 200 g. wt.), of both sexes, were used. Animals were fed on ordinary diet, in a well equipped, ventilated and conditioned animal house .
- **Drugs :**
- \* Praziquantel (Biltricide) (Bayer Co.).
  - \* Levimasole (ketrax) (Cid Co.).
  - \* Chloroquine phosphate (Alexandria Co.).
  - \* Sulphamethoxazole (SMZ) }
  - \* + Trimethoprim (TMP) } (Sutrim) (Memphis Co.).
  - \* Clindamycin Hcl hydrate  
                                 (Dalacin-C)                                  (Upjohn Co.).

The doses were calculated per animal by extrapolation of the human therapeutic doses according to Paget and Barnes table for interspecies dosage conversion (1964) .

All drugs were dissolved in distilled water and different concentrations were prepared according to animal weight . Each animal received 0.2ml of the tested drug solution containing the proper calculated dose orally , using polythene tubes fitted to tuberculin syringe . In acute toxoplasmosis the drugs were given once , while in chronic toxoplasmosis , the drugs were given daily for seven days .

- **Parasite :** RH strain of toxoplasma (the trophozoite form) was maintained in the laboratory through mice by regular

intraperitoneal passage carried out every three days . The infected exudate was withdrawn from the peritoneal cavity of previously infected mice on the third day of infection and inoculated into new mice . Peritoneal washing was done to detect the parasite in the peritoneal cavity of the infected mice . Examination of unstained sample was done using high power objective lens . Counting of the parasite was done on a counting slide through aspiration of the peritoneal exudate on the fourth day from previously infected mice . The peritoneal exudate was diluted with sterile saline and the degree of dilution varies according to the number of parasites required for each animal . The mean of two counts of toxoplasma trophozoite/cmm was taken to minimize the error of counting .

— **Experimental design :**

**A ) Acute toxoplasmosis in mice :**

Animals were divided into six groups , each of ten mice. Each group was given the tested drug dissolved in water orally , the sixth group was given saline to serve as a control . Two days after administration of these drugs , mice in the six groups were inoculated intraperitoneally with RH strain of *Toxoplasma gondii* (about 200,000 trophozoite / 0.2 ml for each mouse) . Mice were closely observed daily , and the mortality rate in the tested groups was recorded for ten days .

**B ) Chronic Toxoplasmosis in rats :**

Chronic infection in rats was achieved by intraperitoneal (I . P.) inoculation of about 400,000 *Toxoplasma* trophozoite / 0.2 ml into each rat .

six groups , each of ten albino rats , were inoculated I.P. with *Toxoplasma gondii* . One week after infection , the tested drugs were given orally to the first five groups , while the sixth was given saline to serve as a control . Two weeks later , half of the rats from each group were dissected . Specimens from liver , spleen , and brain were preserved in 70% normal saline and were processed to paraffin sections at 5  $\mu\text{m}$  and stained with haematoxylin and eosin for histopathological study . Compression smear from each organ after complete dryness , fixed in methyl alcohol acetone free , and stained with Giemsa stain were examined under the microscope . After another two weeks the previous steps were done for the rest of the infected animals .



## RESULTS

### A ) Acute toxoplasmosis in mice :

The mortality rate in the tested animals is shown in table ( 1 ) :

In groups I, II, III and VI, examination of their peritoneal exudates revealed the presence of trophozoite stages of *Toxoplasma gondii* . whereas in groups IV and V, the trophozoite stages of the parasite were detected in the peritoneal exudate of the dead animals, but completely eradicated from the peritoneal exudate of survived mice .

**Table (I) : Mortality rate in rats in acute Toxoplasmosis, under various drugs.**

Group	Drugs ( doses / mouse )	No. of dead animals along the observation days										The final % mortality
		1	2	3	4	5	6	7	8	9	10	
I	Praziquantel 5 mg ( I )	—	—	1	4	3	2	—	—	—	—	100
II	Levamisole 0.5 mg ( II )	—	—	—	5	3	2	—	—	—	—	100
III	Chloroquine Phosphate 4 mg ( III )	—	—	—	5	4	1	—	—	—	—	100
IV	Sulphamethoxazole (SMZ) + Trimethoprim ( TMP ) 4 mg ( IV )	—	—	—	3	2	—	1	—	1	—	70
V	Clindamycin Hcl hydrate 3 mg ( V )	—	—	—	4	2	1	—	—	1	—	80
VI	Untreated control ( VI )	—	—	—	5	4	1	—	—	—	—	100

**B ) Chronic toxoplasmosis in rats :****I . Histopathological changes in the brain , liver and spleen ;  
two and four weeks after drug administration :**

Tables II , III and IV show these histopathological changes occurring in the brain , liver and spleen respectively , in chronic toxoplasmosis in white rats :

Table ( II ) : Histopathological changes in the brain two and four weeks after treatment in chronic toxoplasmosis in white rats .

Group	Drugs doses / rat	Changes in the subarachnoid space			
		Congestion of blood vessels		Lymphocyte infiltration	
		After 2 weeks	After 4 weeks	After 2 weeks	After 4 weeks
I	Praziquantel (32 mg)	moderate (+ +)	mild (+)	moderate (+ +)	mild (+)
II	Levamisole (2 mg)	moderate (+ +)	mild (+)	moderate (+ +)	mild (+)
III	Chloroquine phosphate (27 mg)	moderate (+ +)	mild (+)	moderate (+ +)	mild (+)
IV	Trimethoprim + Sulpha- methoxazole (29 mg)	mild (+)	mild (+)	No change (-)	No change (-)
V	Clindamycin Hcl hydrate (22 mg)	mild (+)	mild (+)	No change (-)	No change (-)
VI	Untreated control	severe (+ + +)	moderate (+ +)	moderate (+ +)	moderate (+ +)

Changes are shown in Figs . ( 1, 2, 3, 4, 5 and 6 ).

mild (+), moderate (+ +), severe (+ + +), no change (-)

Table ( III ) : Histopathological changes in the liver , two and four weeks after treatment in chronic toxoplasmosis in white rats .

Group	Drugs doses/rat	Congestion of the sinusoids		Lobular Necrosis		Lymphocytic infiltration In the portal tracts	
		2 weeks	4 weeks	2 weeks	4 weeks	2 weeks	4 weeks
I	Praziquantel ( 32 mg )	severe ( + + + )	moderate ( + + )	mild ( + )	mild ( + )	severe ( + + + )	moderate ( + + )
II	Levinsasole ( 2 mg )	moderate ( + + )	moderate ( + + )	mild ( + )	mild ( + )	severe ( + + + )	moderate ( + + )
III	Chloroquine Phosphate ( 27 mg )	moderate ( + + )	moderate ( + + )	mild ( + )	mild ( + )	severe ( + + + )	moderate ( + + )
IV	Trimethoprim + Sulphamethoxazole ( 29 mg )	mild ( + )	mild ( + )	mild ( + )	No change ( — )	mild ( + )	mild ( + )
V	Clindamycin Hcl hydrate ( 22 mg )	mild ( + )	mild ( + )	mild ( + )	No change ( — )	mild ( + )	mild ( + )
VI	Untreated Control	moderate ( + + )	moderate ( + + )	mild ( + )	mild ( + )	severe ( + + + )	moderate ( + + )

Changes are shown in Figs . ( 7, 8, 9, 10, 11, 12 ) .

mild ( + ), moderate ( + + ), severe ( + + + ), no change ( — )

**Table ( IV ) : Histopathological change of the spleen, two and four weeks after treatment in chronic toxoplasmosis in white rats.**

Group	Drugs doses / rat	Congestion of the red pulp		Hyperplasia of the lymphoid follicles	
		2 weeks	4 weeks	2 weeks	4 weeks
I	Praziquantel ( 32mg )	moderate ( + + )	mild ( + )	moderate ( + + )	mild ( + )
II	Levimasole ( 2 mg )	moderate ( + + )	mild ( + )	moderate ( + + )	mild ( + )
III	Chloroquine Phosphate ( 27 mg )	moderate ( + + )	mild ( + )	moderate ( + + )	mild ( + )
IV	Trimethoprim + Sulphametho xazole ( 29 mg )	mild ( + )	mild ( + )	mild ( + )	No change ( — )
V	Clindamycin Hcl hydrate ( 22 mg )	moderate ( + + )	mild ( + )	mild ( + )	No change ( — )
VI	Untreated control	severe ( + + + )	moderate ( + + )	moderate ( + + )	moderate ( + + )

Changes are shown in Figs . ( 13, 14, 15 ) .

mild ( + ), moderate ( + + ), severe ( + + + ), no change ( — )

### 11. Examination of the brain , liver and spleen by direct smear stained with Giemsa stain :

In the liver and spleen, toxoplasma cysts were not detected in their smears in all the groups , neither after two weeks nor after four weeks post-treatment . Meanwhile ,these cysts were detected in the brain smears in all smears two weeks and four weeks after treatment in groups I, II, III and VI. But in groups IV and V, toxoplasma cysts were detected in all smears two weeks after treatment, and were absent in all smears four weeks after treatments (Fig . 16 ).

### DISCUSSION

In acute toxoplasmosis in this study, the drugs administered two days before infection, served as a trial to test and evaluate their prophylactic effects in the course of *Toxoplasma gondii* infection in mice .

It was shown in this study that , Praziquantel ( 5 mg / mouse ), levimasole ( 0.5 mg/mouse) and chloroquine phosphate (4 mg/mouse) had no prophylactic effect on the course of acute experimental toxoplasmosis in mice when administered two days before infection as a single prophylactic dose, since the mortality rates were 100% in infected animals that was similar to the control untreated group. These results are consistent with those of El-Rifaie (1974) who found that antibilharzial drugs had no effect in treatment of experimental toxoplasmosis in mice. Also Youssef et al. ( 1985 ) stated that levimasole in a dose of 6 mg/kg day for three successive days starting one day before infection of guinea pigs at mid-pregnancy with *toxoplasma gondii* led to termination of pregnancy. Again El-Rifaie (1974) proved that chloroquine phosphate (200 mg/kg) had no effect in treatment of acute toxoplasmosis in mice.

The previous drugs need more studies as regards their dosage, duration of treatment and timing of intake, to clarify their prophylactic effects-if any-in the course of the disease.

Meanwhile, it was shown in this study that trimethoprim-sulphamethoxazole (4 mg/mouse) and clindamycin Hcl hydrate (3 mg/mouse) when given two days before infection led to survival of 30 % and 20 % of the tested mice respectively, with eradication of the organism from the peritoneal exudate of survived mice. These results were in agreement with that of Grossman and Ramington (1979) who stated that treatment of acute toxoplasmosis in mice with trimethoprim (200 mg/kg) and sulphamethoxazole (100 mg/kg) when continued for 14 days led to mortality rate of 60 % of tested mice, and also consistent with that of Araujo and Remington (1974) who stated that clindamycin Hcl hydrate when used immediately after infection with *Toxoplasma gondii* in a dose of 3 mg/mouse for ten days, led to mortality rate of 50 % of tested mice.

In spite of the low cure rate in this study with the latter two drugs, it seems reasonable to try further studies with them in other doses and treatment schedules for a possible effect on the course of toxoplasma infection.

In chronic toxoplasmosis in this study, it was seen that praziquantel (32 mg/rat), levimasole (2 mg/rat) and chloroquine phosphate (27 mg/rat) had no effects on the course of chronic toxoplasmosis in rats. However, trimethoprim-sulphamethoxazole (29 mg/rat) and clindamycin Hcl hydrate (22 mg/rat) led to eradication of toxoplasma cysts from the brains with less histopathological changes of the brain, liver, and spleen of the treated rats. Again, these results focus on the two drugs that gave partial effects in acute toxoplasmosis, that invite the researchers for a more detailed and programmed studies of these drugs in toxoplasmosis.

## REFERENCES

- **Araujo, F.G. and Remington, J.S. (1974)** : Effect of clindamycin on acute and chronic toxoplasmosis in mice. *Antimicrob. Agen. Chem.*, 5 (6) : 647-651.
- **Beverley, J.K.A. (1974)** : Some aspects of toxoplasmosis, a world wide Zoonosis. *Parasitic Zoonosis*, 1-25.
- **El-Dasouqi, I.T. (1978)** : The genesis of congenital toxoplasmosis. *J. Egypt Soc. Parasit.*, 8 (2): 363-372.
- **El-Rifaie, S.A.S. (1974)**: Studies of the effect of different therapeutic agents on toxoplasma. A thesis of M.D. Degree in Parasitology, Cairo University.
- **Frenkel, J.K. (1953)**: Comparative pathology of toxoplasmosis. VI Congr. Int. Microb. Roma, Riass. Comunic., 2:554-555.
- **Goldsmith, R.S. (1989)**: Infectious diseases: Protozoal (Chapter 28), in: *Current Medical Diagnosis & treatment*, Appleton and Lange, 1988.
- **Grossman, P.L. and Ramington, J.S. (1979)**: The effect of trimethoprim and sulphamethoxazole on *toxoplasma gondii* in vitro and in vivo. *Am. J. Trop. Med. Hyg.*, 28 (3): 445-455.
- **Heyneman, D. (1989)**, *Medical Parasitology*, In *Medical microbiology*, 18 th edition. p: 230-32. Appleten & Lange. Norwalk. Connecticut/San Mateo, California.
- **Paget, G.E. and Barnes, J.M. (1964)**: (a) Evaluation of results: Qualitative application in different species P. 160. (b) Toxicity tests, P. 135-166. In: *Evaluation of drug activities: Pharmacometrics*, Vol. I, Eds Laurence, D.R. and Backarach, A.L. Academic Press, London and New York.

- **Rifaat, M.A.; Salem, S.A.; Azab, M.E.; Beshir, S.R.; Safer, E.H. and El-Shennaay, S.F.A (1981):** Effect of *toxoplasma gondii* on histopathology and histochemistry of reticuloendothelial system in experimental animals. Fohia. Parasitol., 28: 117-124.
- **Schmidt, G.d., and Roberts, L.S. (1985):** Foundations of Parasitology, 3 rd edition, Mosly.
- **Siegel, S.E.; Lund, M.N. and Gelderman, A.H. (1971):** Transmission of toxoplasmosis of leucocyte transfusion. Exc. Med. Microb., 25 : 373.
- **White, R.D. (1990),** Congenital infections. Annual of Clinical problems in Paediatrics, with annotated key references, 3 rd edition by, Roberts, K.B. P: 160-61. Little, Brown and Company Boston/Toronto/London.
- **Wright, W.H. (1975) :** A summary of newer knowledge of toxoplasmosis. Am. J. Clin. Path., 28: 1-7.
- **Youssef, M.Y.; El-Ridi, A,M.S.; Arafa.; M.S.; and El-Sayed, W.M. (1985) :** Effect of levimasole on toxoplasmosis during pregnancy in guinea pigs. J. Egypt Soc. Parasit., 15 (1) : 41 - 48.



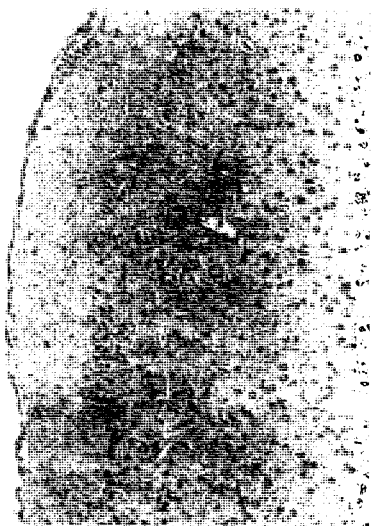


Fig. (1): Praziquantel treated *Toxoplasma* infected group after two weeks. Brain showed moderate congestion of Bl. Vs. and moderate lymphocytic infiltration in the subarachnoid space. ( H & E x 150 ).




Fig. (2) : Praziquantel treated *Toxoplasma* infected group after four weeks. Brain showed mild congestion of Bl. Vs. and mild lymphocytic infiltration in the subarachnoid space ( H & E x 150 ).




Fig. (3) : TMP and SMZ treated *Toxoplasma* infected group after two weeks. Brain showed mild congestion of Bl. Vs. in the subarachnoid space ( H & E x 150 ).



Fig. (4) : TMP and SMZ treated *Toxoplasma* infected group after four weeks. Brain showed mild congestion of Bl. Vs. in the subarachnoid space ( H & E x 150 ).

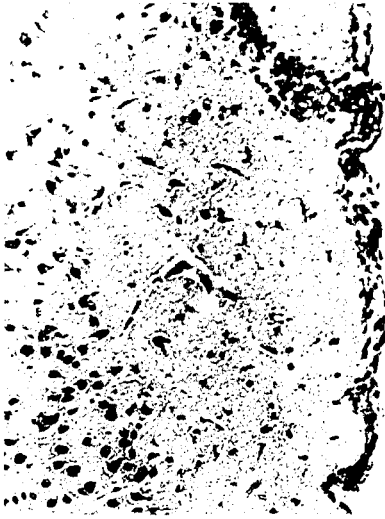


Fig. (5) : Infected control group after two weeks. Brain showed severe congestion of Bl Vs. and severe lymphocytic infiltration in the subarachnoid space. ( H & E x 150 ).



Fig. (6) : Infected control group after four weeks. Brain showed severe congestion of Bl Vs. and severe lymphocytic infiltration in the subarachnoid space. ( H & E x 150 ).

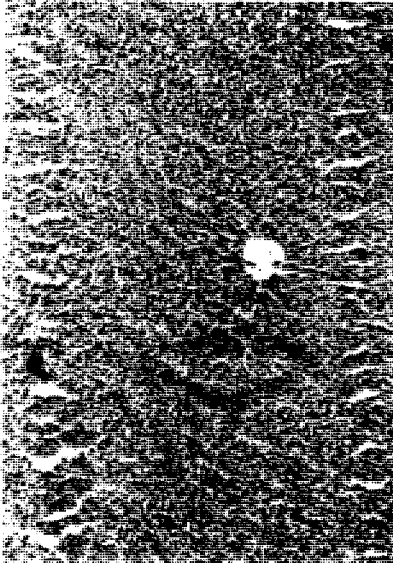


Fig. (7) : Praziquantel treated *Toxoplasma* infected group after two weeks. Liver showed severe congestion of sinusoids and severe lymphocytic infiltration in the portal tract ( H & E x 90 ).

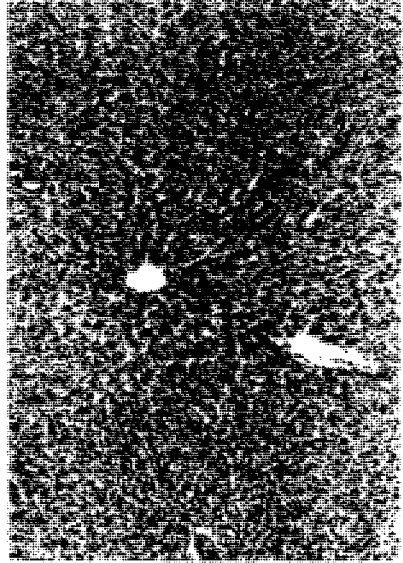


Fig. (8) : Praziquantel treated *Toxoplasma* infected group after four weeks. Liver showed severe congestion of sinusoids and severe lymphocytic infiltration in the portal tract ( H & E x 90 ).

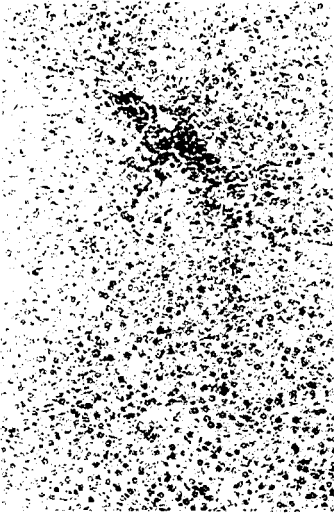

Fig. (9) : TMP and SMZ treated *Toxoplasma* infected group after two weeks. Liver showed mild congestion of sinusoids and mild lymphocytic infiltration in the portal tract. ( H & E x 90 ).




Fig. (10) : TMP and SMZ treated *Toxoplasma* infected group after four weeks. Liver showed mild congestion of sinusoids and mild lymphocytic infiltration in the portal tract. ( H & E x 90 ).

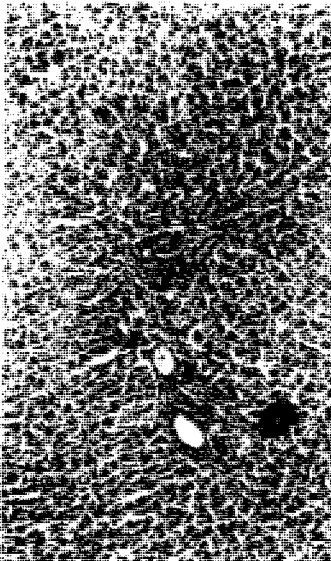


Fig. (11) : Infected control group after two weeks. Liver showed moderate congestion of sinusoids and severe lymphocytic infiltration in the portal tract ( H & E x 90 ).

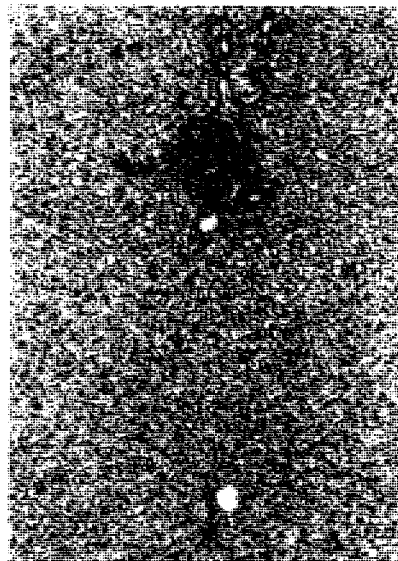


Fig. (12) : Infected control group after four weeks. Liver showed moderate congestion of sinusoids and severe lymphocytic infiltration in the portal tract ( H & E x 90 ).




Fig. (13) : Praziquantel treated *Toxoplasma* infected group after two weeks. Spleen showed moderate congestion of the red pulp and moderate hyperplasia of lymphoid follicles ( H & E x 90 ).



Fig. (14) : TMP and SMZ treated *Toxoplasma* infected group after two weeks. Spleen showed mild congestion of the red pulp and mild hyperplasia of the lymphoid follicles( H & E x 90 ).




Fig. (15) : Infected control group after two weeks. Spleen showed severe congestion of the red pulp and moderate hyperplasia of the lymphoid follicles. ( H & E x 90 ).




Fig. (16) : Giemsa stained brain smear showing *Toxoplasma* brain cyst. ( X 300 ).

## ملخص البحث

أجريت هذه الدراسة على الفئران البيضاء والجرذان لمعرفة تأثير بعض العقاقير على طفيل التوكسوبلازما في طورها الحاد والمزمن . وقد قسمت الحيوانات إلى ست مجموعات تتكون كل منها من عشرة حيوانات من الفئران أو الجرذان ، وقد استعملت الأدوية التالية مرتبة بالمجموعات - برازي كوانتيل ( مضاد للبلهارسيا ) - ليفيازول ( مضاد للديدان ) - كلوروكوين ( مضاد للملاريا ) - (سلفاميثوكسازول + تراميثوبريم) و كلنداميسين ( مضادين حيويين ) .

واعطيت المجموعة السادسة محلول ملحي لتعمل كمجموعة قياسية ، وفي الطور الحاد للطفيل اعطيت الفئران البيضاء الصغيرة الأدوية في جرعة واحدة قبل العدوى بيومين ، بينما في الطور المزمن للطفيل اعطيت الجرذان الأدوية بعد أسبوع من العدوى .

وقد تبين من الدراسة أن الثلاثة أدوية في الثلاث مجموعات الأولى ليس لها أي تأثير على الطور الحاد أو المزمن للطفيل ، بينما السلفا المركبة والكلنداميسين قللت نسبة الوفيات من الفئران في الطور الحاد وقللت من التغيرات الباثولوجية في المخ والكبد والطحال في الجرذان في الطور المزمن .

ومن هذه النتائج ينصح باجراء مزيد من الدراسات العلمية المختلفة على تأثير تلك العقاقير - وخاصة عقاري السلفا المركبة والكلنداميسين - على طفيل التوكسوبلازما من أجل الوصول إلى تأثيرها العلاجي في حالات العدوى بالتوكسوبلازما .